


Virtual Navigator

Thyroid - Neck



Introduction

In the last decade, there has been a rapid refinement in the diagnosis and therapy in the neck, especially in the field of thyroid disease. Ultrasound plays a fundamental role in the management of thyroid neoplasm and in particular in the management of recurring neck problems after thyroidectomy. Ultrasound can be used in many ways, such as:

- Guiding fine needle aspiration
- Planning surgery
- Guiding ablation procedures
- Tagging lesions before surgery
- Intraoperative localization of lesions


Bi-dimensional Navigation: an assisted step towards diagnosis

The localization of lesions with real-time ultrasound while taking advantage of a secondary 2D technology is a significant challenge in everyday clinical practice without technological support.

Nuclear medicine provides specific functional information which is useful for detecting pathologies, but establishing a cognitive correlation between a US finding and Scintiscan can be difficult. In particular, guessing the correct position of the probe with respect to 2D Thyroid Scintiscan images, ensuring high precision and ideally tracking it, is almost impossible with standard ultrasound.

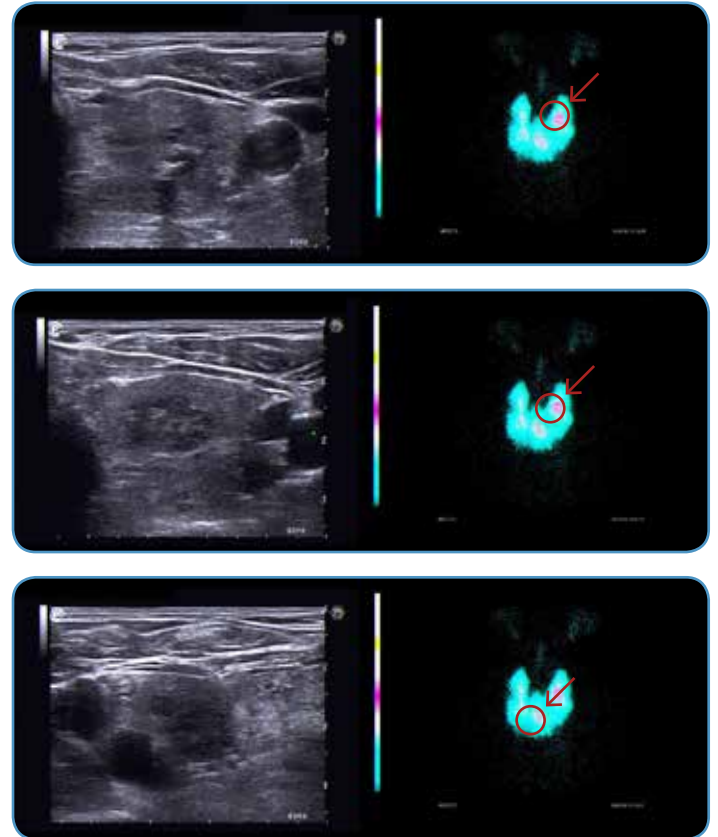
Detailed detection is essential, especially in multi-nodular goiters, to avoid performing ultrasound-guided FNA or biopsies on non-pathological nodules by precisely locating the hot nodules. On the other hand, hot nodules can be precisely targeted on a US scan if percutaneous ablation is required.

BodyMap



BodyMap i is an exclusive technology which enables the real-time visualization of the probe position on a second system next to any kind of DICOM 2D image, such as Scintiscan, SPECT, MRI, PET, XRay and many more.

The coregistration between the ultrasound and the second imaging modality takes less than one minute and there is an option to take a picture of the body area under examination (Bodymark) with a BodyCamera.



Real-time tracking of the probe with 2D Thyroid Scintiscan: on the left the ultrasound scan and on the right the probe position (red circle) in a secondary imaging (Scintiscan).

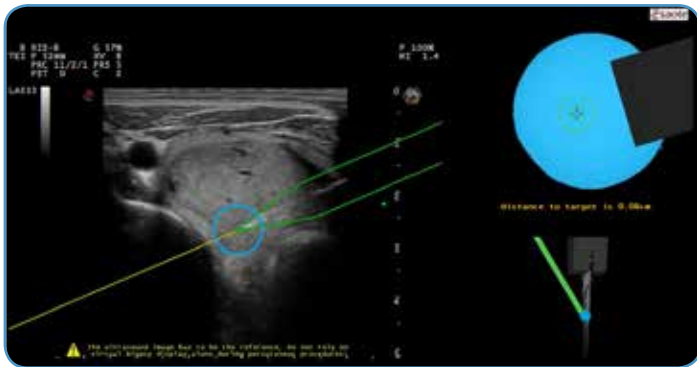
“Ultrasound can work miracles but it lacks the functional and user-friendly 3D information of other imaging modalities”

Prof. Giancarlo Bizzarri, Regina Apostolorum Hospital - Albano Laziale, Rome

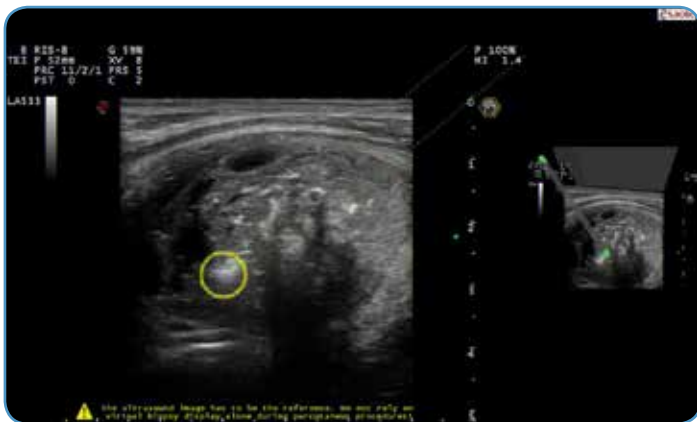Virtually Guided Biopsy Procedures: a further step toward interventional

Virtual Biopsy combined with Intelligent Positioning can increase confidence during real-time ultrasound biopsy procedures. Using virtual tracking of the needle, the target can be reached quickly, precisely and safely. The physical needle is indicated by a virtual needle directly on the real-time ultrasound image with an accurate 3D representation of the probe, scanning plane and path to the target.

Colored targets of regular and irregular shapes can be visualized. The needle path is also visualized before the insertion of the real needle, for advance planning of the best insertion path to avoid critical structures.



Intelligent Positioning represents the needle tip as a fixed point in space, with the target as a moving object seen from the needle tip's viewpoint: the needle becomes a targeted viewfinder.



A step ahead with Fusion Imaging and 3D Real-time Neck Navigation

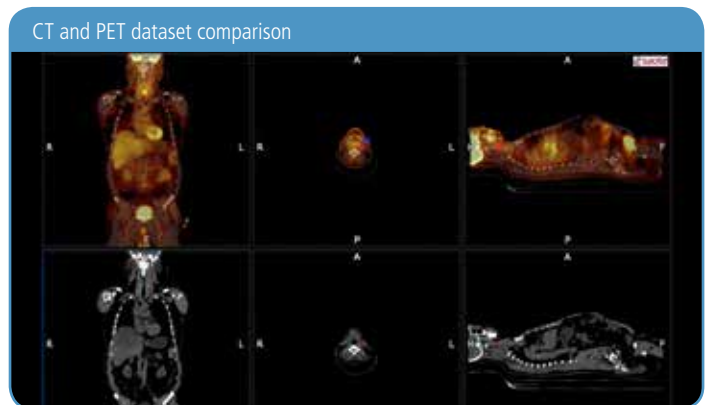
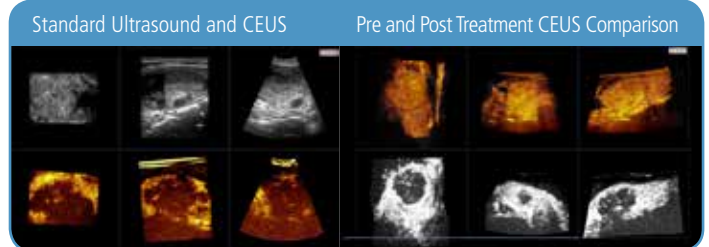
Virtual Navigator is Esaote's revolutionary Technology for Fusion Imaging that displays CT, MR and PET images side-by-side with real-time Ultrasound.

US	Real-time	MR Extended field of view
	Low cost examination	CT No patient depending
	No patient irradiation	PET Easy image interpretation

The Esaote Virtual Navigator offers the chance to perform real-time Fusion of US with multiple imaging systems. This technology merges the real-time capabilities of Ultrasound such as Doppler, CEUS and Elastasonography with functional and 3D information from other systems.

Virtual Navigator can increase your diagnostic confidence in:

- **Visualizing/analyzing** different datasets for diagnostic purposes with real-time multi-modal Fusion Imaging through its Autofusion technology

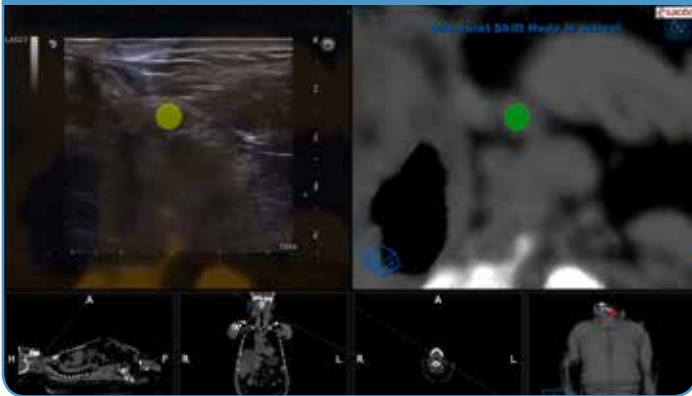


“US–PET fusion and navigation can accurately guide a US biopsy or FNA. In this case PET allowed the US localization of the pathological node and real-time US allowed accurate sampling”

MD. Antonio Bianchini, Regina Apostolorum Hospital - Albano Laziale, Rome

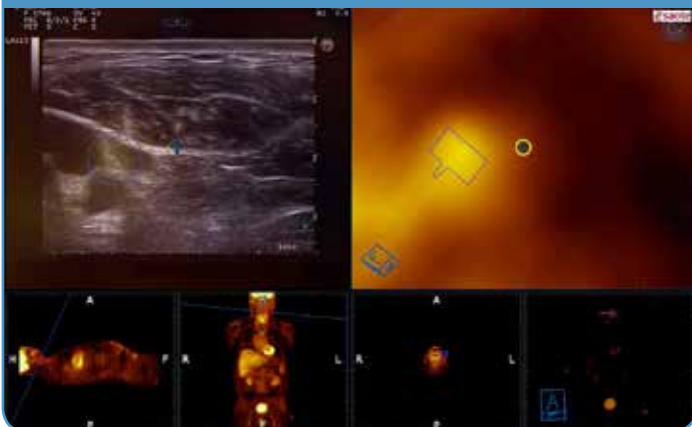
- **Planning** the best scanning and targeting approach

Defining the target and correct approach for an interventional procedure with ultrasound and CT



- **Guiding** the operator during Interventional Procedures such as FNA (Fine Needle Aspiration)

FNA for the neck lymph node procedure with real-time ultrasound fused with PET on a patient who underwent surgery for a laryngeal carcinoma. The lymph node is visible on the PET scan as an area of hyper-metabolism in the left cervical area (level 2)



The real-time visualization of ultrasound and CT/MR/PET imaging is obtained by connecting the unit to an electromagnetic tracking system, which informs the operator about the position and the orientation of the probe in a 3D environment, ensuring fast, easy and accurate scanning. Tracking of the patient's movements is enabled by the Motion Control Sensor activation.

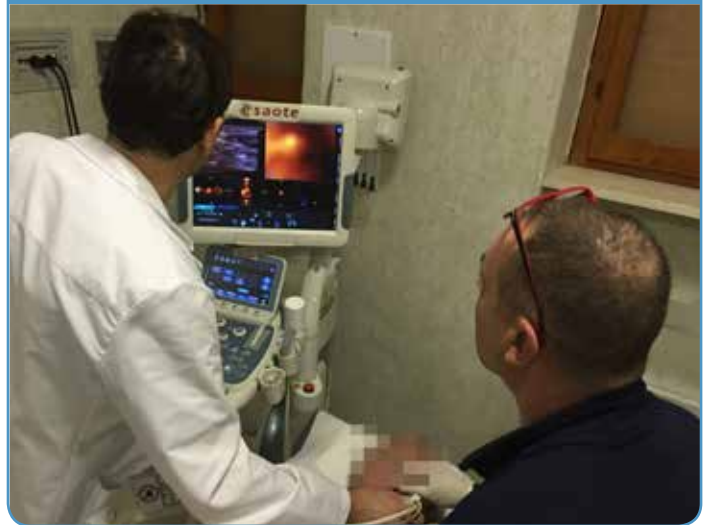Ultrasound findings can also be embedded in high-resolution 3D CT and MRI datasets to obtain user-friendly localization maps.

The results are impressive for targeted resection of Papillary Thyroid Cancer Nodal Metastases and recurrences.

“The idea is to make a fusion of neck ultrasound with Neck 3D MRI or MDCT. Pathological findings on neck ultrasound can be visualized with a more user-friendly anatomical 3D representation”

Prof. Giancarlo Bizzarri, Regina Apostolorum Hospital - Albano Laziale, Rome

Prof. Giancarlo Bizzarri, Regina Apostolorum Hospital, Director of Interventional Radiology Department



References

1. Ragazzoni F et al., **High diagnostic accuracy and inter-observer reliability of real-time elastography in the evaluation of thyroid nodules**, Ultrasound in Medicine & Biology, July 2012; 38(7): 1154-62
2. Calliada F, Canepari M, Ferraioli G, Filice C, **Esaote: ElaXto Sonoelastography, in Sono-Elastography Main Clinical Applications**, EDIMES Srl Edizioni Medico Scientifiche – Pavia, ISBN 978-88-88541-09-9
3. Chin S, Perlas A, **Needle Visualization in Ultrasound-Guided Regional Anesthesia: Challenges and Solutions**- Regional Anesthesia and Pain Medicine, 2008; 33 (6): 532–544.
4. Duger C, Isbir A, **The Importance of Needle Echogenicity in Ultrasound Guided Axillary Brachial Plexus Block: A Randomized Controlled Clinical Study**- International Journal Medical Sciences, 2013; 10(9): 1108–1112.
5. Koski J, Hammer H, **Ultrasound-guided procedures: techniques and usefulness in controlling inflammation and disease progression** - Rheumatology, Oxford Journal, 2012; Vol 51: vii31-vii35.